

# Comparative Study Ultrasound Guided Abdominal Field Blocks versus Port Infiltration in Laparoscopic Cholecystectomies for Post-Operative Pain Relief

Shazia Shafi, Nusrat Jehan\* and Kouser Benazir

Department of Anesthesiology & Critical Care, Government Medical College, Srinagar, India

\*Corresponding author: Nusrat Jehan, Department of Anesthesiology & Critical Care, Government Medical College, Srinagar, India, E-mail: Jehan\_1276@yahoo.co.in

Received date: May 13, 2021; Accepted date: May 27, 2021; Published date: June 03, 2021

Citation: Shafi S, Jehan N, Benazir K (2021) Comparative Study Ultrasound Guided Abdominal Field Blocks versus Port Infiltration in Laparoscopic Cholecystectomies for Post-Operative Pain Relief. Int J Anesth Pain Med Vol.7 No.4: 46

## Abstract

**Background:** Effective post-operative analgesia after laparoscopic cholecystectomy is important because it facilitates early amelioration, ambulation and short hospital stay.

**Aim:** To compare the postoperative analgesic efficacy of ultrasound guided abdominal field blocks with port site infiltration with ropivacaine in laparoscopic cholecystectomy.

**Methods:** An observational study was conducted in the Postgraduate Department of Anesthesiology and Critical Care Medicine in collaboration with the Department of General Surgery, Government Medical College, Srinagar from October 2017-December 2018. Patients were randomized into two groups to receive either local anesthetic infiltration of the laparoscopy port sites (n=40, Group A/standard group) and USAFBs (n=40, Group B/study group) using a total dose of 30 ml of ropivacaine 0.2% with sterile technique. Randomization was done by flipping of coin method. The primary objective was to measure magnitude of pain in first 24 hours using Numeric Rating Scores (NRS). To estimate opioid consumption in first 24 hours postoperatively. To assess the quality of pain relief and patient satisfaction on a four-point Patient satisfaction scale. Statistical analysis was done using SPSS version 21. Data were compared using the Chi-square test and students' t-test.

**Results:** Duration of analgesia was significantly longer in Group B than group A. Upon inter group comparison of A vs. B the results were statistically significant (p value <0.001). At all time in 24 hrs. Postoperative period (1, 2, 4, 6, 12 and 24 hrs.) NRS score was least in group B then group A with statistically significant difference (p-value <0.001). The overall tramadol consumption in Group A was approximately twice ( $107.5 \pm 61.55$  mg) as compared to Group B ( $56.3 \pm 39.53$  mg).

**Conclusion:** STA block in addition with rectus abdominis sheath block is a good alternative for providing perioperative analgesia for upper abdominal surgery such as laparoscopic cholecystectomy and can cover the conventional anatomical port sites as well.

**Keywords:** Laparoscopic cholecystectomy; Abdominal field blocks; Ropivacaine; Local anaesthetic infiltration

## Introduction

Laparoscopic cholecystectomy pain is complex in nature, with wide inter-individual variation in its severity and duration. The pattern does not resemble pain after other laparoscopic procedures, suggesting that analgesic treatment should be multimodal [1]. Postoperative analgesia is a major component of perioperative care and local anaesthetic techniques are more effective than systemic analgesia regardless of the operation and mode of delivery [2].

Regional analgesia of the abdominal wall can provide good analgesia for a variety of surgical operations especially when used as part of a multimodal technique. Haemodynamic effects are minimal as spread of local anaesthetic is limited to the abdominal wall [3].

The use of ultrasound greatly facilitates the performance of TAP block and eliminates the need to feel subjective "pops" (indicating loss of resistance as the needle pierces the external oblique fascia and internal oblique muscle), which is necessary for the correct performance of TAP block by the traditional landmark technique, but is a subtle and imprecise endpoint. However, using surface ultrasound, the muscle layers of the Antero lateral abdominal wall are easily identified and accurate needle placement and deposition of local anesthetic can be facilitated by using 'real time' imaging. The success rate and safety of TAP block may be improved by the use of ultrasound [4].

Abdominal field blocks comprise of STA (Subcostal Transversus Abdominis) with bilateral posterior rectus sheath block. STA block provides effective analgesia to anterolateral upper abdominal wall, but its spread is limited by the lateral border of the rectus sheath, limiting its analgesic effect in midline and necessitating modification of port sites. Hebbard et al. described the achievement of this peripheral block by an ultrasound guided subcostal oblique approach, which allowed efficient analgesia in both the upper and lower abdomen, and a lower rate of complications due to the direct ultrasound visualization. Subcostal transversus abdominis plane block is efficient in

surgeries such as gastrectomy, laparoscopic bariatric procedure, liver transplant, open hepato-biliary, appendectomy or renal surgery [5-7] Only a few studies have been published regarding the STAP block approach in laparoscopic cholecystectomy, being heterogeneous concerning the procedure or the postoperative analgesic regimen [8,9].

## Methodology

After obtaining the ethical clearance from Institutional Ethical Committee the present observational study was conducted in the Postgraduate Department of Anaesthesiology and Critical Care Medicine in collaboration with the Department of General Surgery, Government Medical College, Srinagar from October 2017 – December 2018. A total of 80 samples for this study with ASA I/II (American Society of Anaesthesiologists physical status classification) scheduled for laparoscopic cholecystectomy were evaluated for the efficacy of port site infiltration with ultrasound guided abdominal field blocks with 30 ml of 0.2% ropivacaine

Patients selected for study were admitted at least 24 hours prior to surgery. Preanaesthetic check-up was done at that stage. A thorough history including history of any comorbid disease, previous history of anaesthetic exposure, medication intake and allergy to any drug was also elicited. General physical examination as well as systemic examination of cardiovascular system, respiratory system, central nervous system was performed. Airway assessment was done to predict the airway status of the patient. Minimum basic investigations were advised. The patients were advised to remain fasting for a period of 8 hours and were explained about the study design and associated risks and benefits.

## Procedure

All patients were transported to the operating room. On arrival to operating room, written informed consent and fasting was confirmed. All the study patients were instructed about the use of the NRS score (Numeric Rating Score) during the pre-operative visit. (NRS score 0-no pain, NRS score 10-worst possible pain). An 18-gauge intravenous (IV) cannula was inserted for fluid infusion. Preoperatively monitoring of electrocardiography, non-invasive blood pressure, oxygen saturation (SpO<sub>2</sub>) was started and baseline values were recorded. Pre-medication with injection pantoprazole 40 mg and pre-operative analgesia with injection Fentanyl 2 mcg/kg were given. Pre-oxygenation with 100% oxygen (O<sub>2</sub>) was done for 3 min. General anaesthesia was induced with injection propofol 2.0-2.5 mg/kg followed by injection atracurium 0.5 mg/kg to facilitate endotracheal intubation. The trachea was intubated with a cuffed endotracheal tube of appropriate size. Anaesthesia was maintained with 60% N<sub>2</sub>O; 40% oxygen with 0.5%-1% isoflurane. Each patient received intraoperative analgesia as injection paracetamol infusion 1 gm. Intermittent boluses of atracurium were used to achieve muscle relaxation. Minute ventilation was adjusted to maintain normocapnia (End Tidal Carbon-Dioxide [EtCO<sub>2</sub>] between 34 and 38 mmHg) and EtCO<sub>2</sub> was monitored. Nasogastric tube of appropriate size was

inserted. Standard monitoring included 3 lead electrocardiography (ECG), Non-Invasive Blood Pressure (NIBP), Pulse Oximetry (SpO<sub>2</sub>), capnography, respiratory rate.

At the end of the surgery, after ensuring full asepsis the transversus abdominis plane block, and posterior rectus sheath block was administered by an ultra sound guided approach before extubation. Patients were randomised into two groups to receive either local anaesthetic infiltration of the laparoscopy port sites (n=40, Group A/standard group) and USAFBs (n=40, Group B/study group) using a total dose of 30 ml of ropivacaine 0.2% with sterile technique. Randomisation was done by flipping of coin method.

In group A preincisional port site infiltration was performed by the surgeon, after the induction of anaesthesia and local anaesthetic were divided equally between port sites. A total of four ports supra umbilical, subxiphoid and two ports in the right subcostal area at mid clavicular and anterior axillary line were made.

In group B, the blocks were performed under ultrasound guidance. High frequency linear probe with a 6-13 MHz frequency (Sonosite M-Turbo) was used. After the induction of anaesthesia, the skin was disinfected with 10% chlorhexidine. Posterior rectus sheath block was administered by placing ultrasonography (USG) transducer 2 cm below the xiphisternum in transverse position. A 90 mm, 22 G Quincke spinal needle was inserted inplane and advanced until the tip rests on the posterior rectus sheath. After negative aspiration, 2 ml of saline was injected to verify needle tip location. When the correct needle position was achieved, 5 ml of 0.2% ropivacaine was injected bilaterally on each side. For right STA block, the USG probe was placed in the midline of the abdomen 2 cm below the xiphisternum and moved right laterally along the subcostal margin to the anterior axillary line. The transversus abdominis muscle was identified lying beneath and extending lateral to the rectus abdominis muscle. A 90 mm, 22 gauge Quincke's spinal needle was then guided, in plane, to a point just inferior to the right costal margin at the anterior axillary line such that the tip was between the transversus abdominis and internal oblique muscle within the neurovascular fascial plane. After careful aspiration to exclude vascular puncture, a test dose of 2 ml normal saline was injected to confirm needle tip placement and determined resistance to flow. Following aspiration, 20 mL of 0.2% ropivacaine was deposited within the plane. Anti-emetic medication was made with intravenous ondansetron 0.15 mg/kg as a slow injection 15 minutes prior to extubation. Thereafter, the residual neuromuscular block was reversed with neostigmine 0.05 mg/kg and atropine 0.02 mg/kg or glycopyrrolate 0.01 mg/kg. Extubation was performed with the patient awake with good breathing efforts and muscle tone. Extubation time was noted and the patient was shifted to the PACU.

## Post-operative management and pain control

Following adequate and complete recovery, patients were transferred to the Post Anaesthesia Care Unit (PACU), where tramadol 50 mg IV infusion over 10 minutes was administered as rescue analgesia if the pain is described as moderate or severe

(the pain was considered mild for NRS=1-3, moderate for NRS=4-6, or severe for NRS=7-9) and repeated as per the need. Evaluation intervals being at 1 hr (in the PACU), 2 h, 4 h, 6 h, 12 h, and 24 h. Pain evaluation and data recording was made and noted. Rescue anti-emetic medication was made with ondansetron 4 mg IV in case patient complained of nausea and vomiting. The primary outcome of the study was to assess the efficacy of postoperative analgesia by NRS in the first 24 postoperative hours at the mentioned intervals. As a secondary outcome, we evaluated time to the first request of analgesia in the post-operative period, opioid consumption in first 24 hours in PACU.

At the end of 24 hours, patients were asked to rank the quality of pain relief on a four point Patient satisfaction scale where:-

- 1-Excellent,                      2-Very Good,  
3-Satisfactory,                  4-Poor

### Statistical methods

The recorded data was compiled and entered in a spreadsheet (Microsoft Excel) and then exported to data editor of SPSS Version 20.0 (SPSS Inc., Chicago, Illinois, USA). Statistical software SPSS (version 20.0) and Microsoft Excel were used to carry out the statistical analysis of data. Continuous variables were expressed as Mean  $\pm$  SD and categorical variables were summarized as frequencies and percentages. Graphically the data was presented by bar and line diagrams. Student's independent t-test was employed for comparing continuous variables Chi-square test or Fisher's exact test, which ever appropriate, was applied for comparing categorical variables. A p-value of <0.05 was considered statically significant. All p-values were two tailed.

### Results

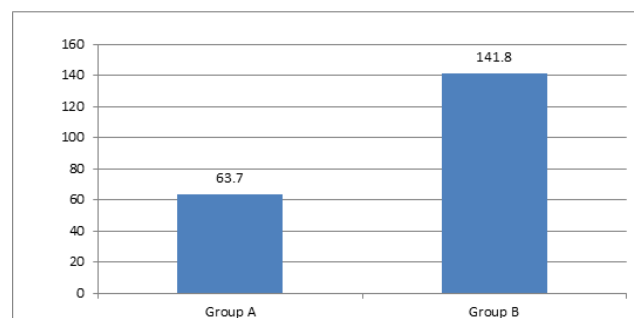
Our examination population included 80 patients to receive either local anaesthetic infiltration of the laparoscopy port sites (n=40, Group A/standard group) and USAFBs (n=40, Group B/study group) using a total dose of 30 ml of ropivacaine 0.2% with sterile technique. Patient's demographics were comparative with no significant differences contrasts among the two groups as far as age, weight, height, ASA class and duration of surgery (Table 1).

Parameters	Group A (n=40)	Group B (n=40)	p value
Age (yrs)	36.0 $\pm$ 13.40	38.2 $\pm$ 11.44	0.432*
Male/Female	17/23	19/21	0.653*
ASA I/II	33/7	31/9	0.576*
Height (cm)	166.3 $\pm$ 4.61	168.4 $\pm$ 5.54	0.264*
Weight (kg)	64.8 $\pm$ 4.31	63.1 $\pm$ 3.65	0.072*
Duration of surgery	45.1 $\pm$ 7.11	48.8 $\pm$ 6.42	0.056*

Mean SD=Standard Deviation; \*level of significance

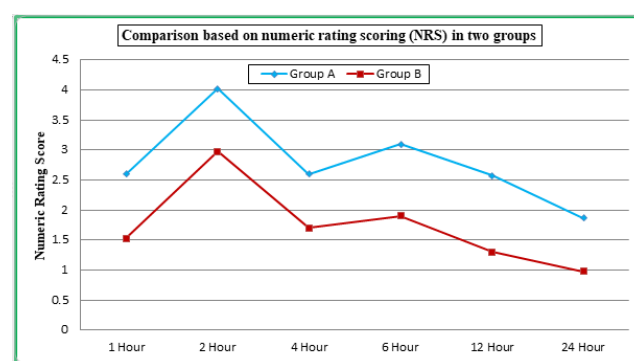
**Table 1:** Demographic profile of the study population.

The time to first request of analgesia was 63.7  $\pm$  11.97 minutes in Group A and 141.8  $\pm$  14.75 minutes in Group B. The statistical difference was significant among the study groups (p-value<0.001) (Figure 1).



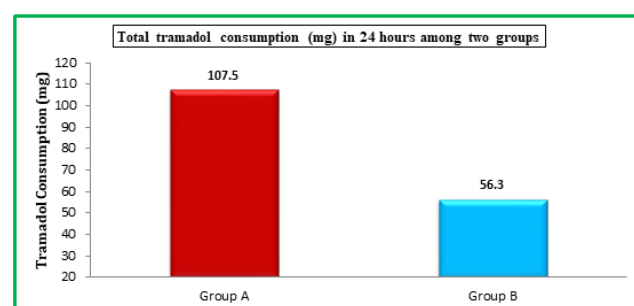
**Figure 1:** The time to first request of analgesia in Group A and Group B.

When comparison was made on numeric rating score (NRS) in two study groups, mean NRS at first hour was 2.60 and 1.53 in Group A and Group B, respectively. At 2 hours, mean NRS was 4.03 and 2.98, at 4 hours it was 2.60 and 1.70, at 6 hours it was 3.10 and 1.90. Mean NRS at 12 hours postoperatively was 2.58 and 1.30 while as at 24 hours it was 1.87 and 0.98, in two study groups, respectively (Figure 2).



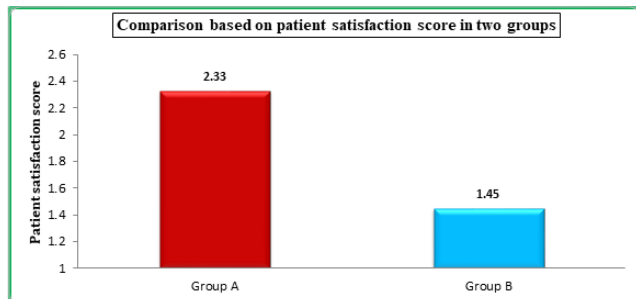**Figure 2:** Comparison based on Numeric Rating Scoring (NRS) in two groups.

In Group A patients mean Tramadol consumption was 107.5 mg while as it was 56.3 mg in Group B patients at 24 hours (Figure 3).



**Figure 3:** Total tramadol consumption (mg) in 24 hours among two groups.

Group A, mean patient satisfaction score was 2.33 while as it was 1.45 in Group B patients (**Figure 4**).



**Figure 4:** Comparison based on patient satisfaction score in two groups.

## Discussion

Laparoscopic surgery, which is considered a minimally invasive surgery, is a modern surgical technique used for various surgeries. Postoperative pain is reduced more speedily compared with open traditional surgeries, but effective analgesic treatment after laparoscopic surgeries have remained a clinical challenge. The patients undergoing laparoscopic surgery tend to expect a painless postoperative period because of common beliefs about this type of surgery. Pain is the main reason for staying overnight in the hospital on the day of surgery and pain is the dominant complaint and the primary reason for prolonged convalescence after laparoscopic surgery. So, it is an essential task to provide adequate postoperative analgesia. For that, we can use various analgesics (opioids and nonopoids) *via* various routes, for example oral, intravenous, neuraxial blockade and intraperitoneal instillation. In addition, growing evidence suggests that the treatment of postoperative pain should be multimodal and opioid sparing to accelerate recovery and avoid potential side effects [10,11].

The physical characteristics including age, gender and weight in two groups in our study were comparable. The mean age of the patients was  $36.0 \pm 13.40$  yrs.,  $38.2 \pm 11.44$  yrs. in groups A, and B, respectively, with a p value of 0.432 (statistically insignificant).

Similarly gender distribution in two groups was comparable with male and female percentage being 42.5% and 47.5% in group A, 57.5% and 52.5% in group B, with a p value of 0.653 (statistically insignificant).

Similarly, all the patients in two groups were comparable regarding the mean weight of the patients. In Group A, weight ranged from 44 to 77 kg with a mean weight of  $59.4 \pm 9.86$  kg. In Group B, weight ranged from 43 to 78 kg with a mean weight of  $61.6 \pm 10.06$  kg. Variation in weight distribution between groups was statistically insignificant (p value of 0.165). Our results were comparable to Vrsajkov et al. [12] in which they conducted a study on 76 patients undergoing laparoscopic cholecystectomy. In their study 38 patients received Subcostal Transversus Abdominis Plane (STAP) block and another 38 patients received

standard postoperative analgesia. In the STAP group, there were 58% male patients and in standard analgesia group 52% patients were females. The weight of the patients in their study groups were  $79.86 \pm 16.78$  and  $80.89 \pm 17.34$  kgs.

The mean duration of post-operative analgesia (1st request of analgesia) in our study was  $63.7 \pm 11.97$  minutes with range from 32-130 minutes in Group A and  $141.8 \pm 14.75$  minutes with range from 81-244 minutes in Group B. Duration of analgesia was significantly longer in Group B than group A. Upon intergroup comparison of A vs. B the results were statistically significant (p-value <0.001). Our results were in agreement with Zhao et al. [13] in which they showed on 905 patients TAP block would result in less analgesic consumption, less requirement of analgesic, and less pain at 2 h and slightly at 6 h but at 24 h after laparoscopic surgery in comparison with usual care alone or placebo block. Our results were also in agreement with study of Gurnaney et al. [14] in which they undertook an observer-blinded, randomized, prospective, observational study to compare the efficacy of ultrasound-guided RSB and LAI in providing postoperative analgesia for umbilical hernia repair.

Their study demonstrated that ultrasound-guided RSB provides superior analgesia in the perioperative period compared with infiltration of the surgical site after umbilical hernia repair. In comparing only the postoperative period, analgesia provided by an ultrasound-guided RSB showed a trend towards statistically significant improvement compared with infiltration of the surgical site. Ra et al. [15] Randomized Fifty-four patients undergoing laparoscopic cholecystectomy into three groups. The patients in Group Control did not receive the US-TAP block. The patients in Group B (0.25) and Group B (0.5) received the US-TAP block with 0.25% and 0.5% levobupivacaine 30 ml respectively. Postoperative NRS and the postoperative demand of rescue analgesics were lower in the groups receiving the US-TAP block (Group B (0.25) and Group B (0.5)) than Group Control.

In our study, Numeric Rating Scale (NRS) was lowest and statistically significant in patients who were given ultrasound guided abdominal field blocks as compared to the patients who received port site infiltration. At all time in 24 hrs Post-operative period (1, 2, 4, 6, 12 and 24 hrs). NRS score was least in group B then group A with statistically significant difference (p-value <0.001). Over all NRS score over 24 hrs also showed statistically significant difference with group A having mean NRS score of  $1.87 \pm 0.778$ , group B having mean NRS score of  $0.98 \pm 0.483$ . Intergroup comparisons showed statistically significant difference with A vs. B, all having p-value <0.001. The results implied that quality of analgesia in postoperative period was best over 24 hrs with group B. Our study was in agreement with Suseela et al. [16] in which they compared ultrasound guided STAP and port infiltration with Bupivacaine in laparoscopic cholecystectomy. Numeric rating score (NRS) for pain was zero at 1 hr in both the groups. That means port-site infiltration and TAP block are effective in providing analgesia in the 1st hr. NRS was significantly lower in Group T compared to Group I at all other timeframes. The mean NRS at first analgesic request was  $6.08 \pm 0.92$  in Group I and  $4.38 \pm 0.49$  in Group T which shows that the intensity of pain was less in TAP group compared to

infiltration. In this study the mean pain scores at 1 hr and 4 hr were less in TAP block compared to port-site infiltration. Our study was also in agreement with Yu et al. [17] in which they did four RCTs, encompassing 96 TAP-block and 100 LAI patients. Patients in the TAP-block group had lower VAS pain scores 24 hours postoperatively compared with the LAI group, both at rest and with movement.

In our study, we found that the NRS was less in patients receiving abdominal field blocks when compared to patients receiving port site infiltration. Rescue analgesia with intravenous bolus dose of 50 mg tramadol was administered at NRS>3. The overall tramadol consumption in Group A was approximately twice ( $107.5 \pm 61.55$  mg) as compared to Group B ( $56.3 \pm 39.53$  mg). The difference was found to be statistically significant ( $p<0.0001$ ). Our study was in agreement with Vrsajkov et al. [12] in which they obtained that tramadol consumption (g) was significantly lower in the STAP group  $24.29 \pm 47.54$  g than in the standard analgesia group  $270.2 \pm 81.9$ . Seven patients in the STAP group received one dose of tramadol on request (NPS  $\geq 6$ ) and two of them request tramadol twice. Our study was also in agreement with Niraj et al. [7] in which they evaluated analgesic efficacy of TAP block in patients undergoing open appendectomy in a randomized controlled double-blinded clinical trial. Fifty-two adult patients undergoing open appendectomy were randomized to undergo standard care or to undergo a right-sided TAP block with bupivacaine. Ultrasound-guided TAP block significantly reduced postoperative morphine consumption in the first 24 hrs ( $p<0.002$ ). Postoperative visual analogue scale pain scores were also reduced in the TAP block group soon after surgery ( $p<0.001$ ). There were no complications attributable to the TAP block. Our study was also in agreement with Siddiqui et al. [18] in which they did a meta-analysis on the clinical effectiveness of transversus abdominis plane block. 86 patients in the TAP block group and 88 in the non-TAP block group. Patients with TAP block required less morphine after 24 hours than those who did not have the block ( $p<0.001$ ). Patients in the TAP block group had less pain up to 24 hours postoperatively. TAP block reduces the need for postoperative opioid use, it increases the time first request for further analgesia, it provides more effective pain relief, and it reduces opioid-associated side effects.

The mean values of postoperative heart rate were significantly low in group B when compared with another group in 1st 6 postoperative hours. The p values at time periods of 1 hr, 2 hrs, 4 hrs, 6 hrs were  $<0.001$  when group B was compared to group A. However, after 6 hrs, the difference became statistically insignificant with p value at 12 hrs being 0.228 and 0.374 at 24 hrs. The results showed that heart rate in group B remained on lower side compared to group A at all the time of assessment in 24 hrs postoperatively but initially the difference was statistically significant in initial 6 hrs (p-value  $<0.001$ ) and thereafter the difference became statistically insignificant at all times with p value  $>0.05$ . The mean values of postoperative systolic blood pressure, diastolic blood pressure and mean blood pressure followed the similar trends. They were comparable at different time intervals among group A and group B.

The mean values of postoperative diastolic blood pressure were significantly low in group B when compared with another group in 1st 6 postoperative hours. When group B was compared to group A, the results were statistically significant and p values at time periods of 0.5 hr, 1 hr, 2 hrs, 4 hrs, 6 hrs were  $<0.001$ . However, after 6 hrs, the difference became statistically insignificant in all groups with p value at 12 hrs and 24 hrs being  $>0.05$ . This showed that hemodynamic parameters in group B remained on lower side compared to group A at all the time of assessment in 24 hrs postoperatively but initially the difference was statistically significant in initial 6 hrs (p-value  $<0.001$ ) and thereafter the difference became statistically insignificant at all times with p-value  $>0.05$ . All the patients were hemodynamically stable throughout in 24 hrs postoperative period. Our results showed that group B was better hemodynamically stable than group A. Statistically significant difference was found in oxygen saturation of two groups, though it was confined within normal limits. It was more in Group B patients at 6, 12 and 24 hr ( $p<0.001$ ). This probably reflects better respiratory efforts in patients with low pain scores. No other adverse effects were observed in both the groups. Our study was in agreement with Bhattacharjee et al. [19] in their study a total of 90 adult female patients American Society of Anesthesiologists physical status I or II were randomized to Group B receiving TAP block with 0.25% bupivacaine and Group N with normal saline followed by general anesthesia. Hemodynamic responses to surgical incision and intraoperative fentanyl consumption were noted. Pulse rate ( $95.9 \pm 11.2$  bpm vs.  $102.9 \pm 8.8$  bpm,  $p=0.001$ ) systolic and diastolic BP were significantly higher in Group N. Median intraoperative fentanyl requirement was significantly higher in Group N (81 mcg vs. 114 mcg,  $p=0.000$ ). Our study was also in agreement with Saxena et al. [20] in which they compared the efficacy of Ultrasound Guided Abdominal Field Blocks (USAFB) with port site infiltrations for post-operative analgesia. Statistically significant difference was found in oxygen saturation of two groups, though it was confined within normal limits. It was more in Group which received ultrasound guided abdominal field blocks at 6, 12 and 24 hrs ( $p<0.05$ ).

The overall patient satisfaction score was much higher with Group B compared to the Group A ( $p<0.001$ ). Our study was in agreement with McDonnell et al. [21] in their study they did a prospective randomized control trial in which Thirty-two adults undergoing large bowel resection *via* a midline abdominal incision were randomized to receive standard care, including patient-controlled morphine analgesia and regular non-steroidal anti-inflammatory drugs and acetaminophen or to undergo TAP block in addition to standard care. All TAP patients reported high levels of satisfaction with their postoperative analgesic regimen with  $p<0.05$ . Our study was also in agreement with Ramkiran et al. [22] in which they did prospective, randomized control, pilot study included 61 patients scheduled for elective laparoscopic cholecystectomy and distributed among three groups, namely:

Group 1: Combined subcostal TAP block with rectus sheath block

Group 2: Oblique subcostal TAP block alone and

Group 3: PSI group as an active control

Combined group had significantly lower pain scores, higher satisfaction scores, and reduced rescue analgesia both in early and late postoperative periods than the conventional PSI group. Ultrasound-guided combined fascial plane blocks is a novel intervention in pain management of patients undergoing laparoscopic cholecystectomy and should become the standard of care.

## Limitation

The present study also has certain limitations. The major disadvantage of STA block is the inability to block visceral pain, which can be substantial, both intra and post operatively. The other major limitation is dermatomal limitation of the block. STA block provides reliable analgesia covering T6-T10 dermatomes.

## Conclusion

STA block in addition with rectus abdominis sheath block is a good alternative for providing perioperative analgesia for upper abdominal surgery such as laparoscopic cholecystectomy and can cover the conventional anatomical port sites as well.

## References

1. Scott NB (2010) Wound infiltration for surgery. *Anaesth* 65: 67-75.
2. Wu CL, Cohen SR, Richman JM, Rowlingson JA, Courpas EG, et al. (2005) Efficacy of postoperative patient-controlled and continuous infusion epidural analgesia versus intravenous patient-controlled analgesia with opioids : A meta-analysis. *Anaesth* 103: 1079-1088.
3. Marhofer P, Greher M, Kapral S (2005) Ultrasound guidance in regional anaesthesia. *Br J Anaesth* 94: 7-17.
4. Bisgaard T, Kehlet H, Rosenberg J (2001) Pain and convalescence after laparoscopic cholecystectomy. *Eur J Surg* 167: 84-96.
5. Hebbard P, Fujiwara Y, Shibata Y, Royse C (2007) Ultrasound-guided transversus abdominis plane (TAP) block. *Anaesth Intens Care* 35: 616-617.
6. Milan ZB, Duncan B, Rewari V, Kocarev M, Collin R (2011) Subcostal transversus abdominis plane block for postoperative analgesia in liver transplant recipients. *Transplant Proc* 43: 2687-2690.
7. Niraj G, Kelkar A, Jeyapalan I, Graff-Baker P, Williams O, et al. (2011) Comparison of analgesic efficacy of subcostal transversus abdominis plane blocks with epidural analgesia following upper abdominal surgery. *Anaesthesia* 66: 465-471.
8. Niraj G, Searle A, Mathews M, Misra V, Baban M, et al. (2009) Analgesic efficacy of ultrasound-guided transversus abdominis plane block in patients undergoing open appendicectomy. *Br J Anaesth* 103: 601-605.
9. Ortiz J, Suliburk JW, Wu K, Bailard NS, Mason C, et al. (2012) Bilateral transversus abdominis plane block does not decrease postoperative pain after laparoscopic cholecystectomy when compared with local anesthetic infiltration of trocar insertion sites. *Reg Anesth Pain Med* 37: 188-192.
10. Pettersson N, Berggren P, Larsson M, Westman B, Hahn RG (1999) Pain relief by wound infiltration with bupivacaine or high-dose ropivacaine after inguinal hernia repair. *Reg Anesth Pain Med* 24: 569-575.
11. Oza PV, Parmar V, Badheka J, Nanavati DS, Taur P, et al. (2016) Comparative study of postoperative analgesic effect of intraperitoneal instillation of dexmedetomidine with bupivacaine and bupivacaine alone after laparoscopic surgery. *J Minim Access Surg* 12: 260-264.
12. Vrsajkov V, Mancic N, Mihajlovic D, Milicevic ST, Uvelina A, et al. (2018) Subcostal transversus abdominis plane block can improve analgesia after laparoscopic cholecystectomy. *Rev Bras Anesthesiol* 68: 149-153.
13. Zhao X, Tong Y, Ren H, Ding XB, Wang X, et al. Transversus abdominis plane block for postoperative analgesia after laparoscopic surgery: A systematic review and meta-analysis. *Int J Clin Exp Med* 7: 2966-2975.
14. Gurnaney HG, Maxwell LG, Kraemer FW, Goebel T, Nance ML, et al. (2011) Prospective randomized observer-blinded study comparing the analgesic efficacy of ultrasound-guided rectus sheath block and local anaesthetic infiltration for umbilical hernia repair. *Br J Anaesth* 107: 790-795.
15. Ra YS, Kim CH, Lee GY, Han JI (2010) The analgesic effect of the ultrasound-guided transverse abdominis plane block after laparoscopic cholecystectomy. *Korean J Anesthesiol* 58: 362-368.
16. Suseela I, Anandan K, Aravind A, Kaniyil S (2018) Comparison of ultrasound-guided bilateral subcostal transversus abdominis plane block and port-site infiltration with bupivacaine in laparoscopic cholecystectomy. *Indian J Anaesth* 62: 497-501.
17. Yu N, Long X, Lujan-Hernandez JR, Succar J, Xin X, et al. (2014) Transversus abdominis-plane block versus local anesthetic wound infiltration in lower abdominal surgery: A systematic review and meta-analysis of randomized controlled trials. *BMC Anesthesiol* 14: 121.
18. Siddiqui MR, Sajid MS, Uncles DR, Cheek L, Baig MK (2011) A meta-analysis on the clinical effectiveness of transversus abdominis plane block. *J Clin Anesth* 23: 7-14.
19. Bhattacharjee S, Ray M, Ghose T, Maitra S, Layek A (2014) Analgesic efficacy of transversus abdominis plane block in providing effective perioperative analgesia in patients undergoing total abdominal hysterectomy: A randomized controlled trial. *J Anaesthesiol Clin Pharmacol* 30: 391-396.
20. Saxena R, Joshi S, Srivastava K, Tiwari S, Sharma N, et al. (2016) Comparative study of ultrasound-guided abdominal field blocks versus port infiltration in laparoscopic cholecystectomies for postoperative pain relief. *Indian J Anaesth* 60: 578-83.
21. McDonnell JG, O'Donnell B, Curley G, Heffernan A, Power C, et al. (2007) The analgesic efficacy of transversus abdominis plane block after abdominal surgery: a prospective randomized controlled trial. *Anesth Analg* 104: 193-197.
22. Ramkiran S, Jacob M, Honwad M, Vivekanand D, Krishnakumar M, et al. (2018) Ultrasound-guided combined fascial plane blocks as an intervention for pain management after laparoscopic cholecystectomy: a randomized control study. *Anesth Essays Res* 12: 16-23.