

Synchronous Airway Lesions in Mandibular Distraction Osteogenesis Patients

Benjamin Caughlin¹,
Corlyne S Mulder¹,
Pravin K Patel² and
Frank Vicari²
Jeffrey C Rastatter³

Abstract

Objective:

1. Determine prevalence and type of synchronous airway lesions (SALs) present in patients undergoing Mandibular Distraction Osteogenesis (MDO) at Lurie Children's Hospital of Chicago
2. To determine whether these SALs affect the surgical outcomes of MDO in relieving airway obstruction

Design: Retrospective Chart Review

Setting: Tertiary care pediatric hospital

Patients, Participants: Patients with micrognathia undergoing MDO and direct laryngoscopy and bronchoscopy (DLB) from 2001-2011. A total of 54 patients were included in the study.

Main Outcome Measure(s): Charts were reviewed for demographics, prevalence and type of SALs, success rate for airway improvement for MDO, and coexisting medical and craniofacial conditions.

Results: A total of 54 patients underwent MDO and of those 21 patients were found who have undergone both MDO and DLB. The incidence of at least 1 SAL was 71.4% in this group. A subgroup of patients less than 24 months had an incidence of SALs that was 78%. Types of SALs encountered include laryngeal edema (57.1%), tracheobronchitis (42.9%), laryngomalacia (33.3%), tracheomalacia (14.3%), bronchomalacia (14.3%), subglottic stenosis (9.5%), and pulsatile airway compression (9.5%). Nine of 21 patients (42.9%) demonstrated airway lesions that have been known to have the potential for more significant airway obstruction than the more minor SALs. These include subglottic stenosis, laryngomalacia, tracheomalacia, bronchomalacia or pulsatile airway compression. Of those patients with MDO and DLB, 19/21 (90.5%) received tracheostomy, and 18/19 of those were decannulated. The patient that was not decannulated had two synchronous airway lesions. There was a second failure that also had a SAL and was determined to be a failure due to lack of clinical improvement after MDO.

Conclusion: There is a high rate of SALs in patients undergoing MDO surgery which can have a significant impact on the anesthesia and acute care practice. In our study population the most common SALs were laryngeal edema, tracheobronchitis and laryngomalacia. Direct laryngoscopy and bronchoscopy should be considered preoperatively for patients undergoing MDO as it has the potential to diagnose other treatable causes of airway obstruction that may affect surgical and anesthetic outcomes.

- 1 Department of Plastic and Reconstructive Surgery, Northwestern University Feinberg School of Medicine, 303 E Chicago Ave, Chicago, IL 60611, USA
- 2 Department of Pediatric Otolaryngology-Head & Neck Surgery, Northwestern University Feinberg School of Medicine, 303 E Chicago Ave, Chicago, IL 60611, USA
- 3 Department of Otolaryngology-Head & Neck Surgery, University of Illinois at Chicago, USA

Corresponding author:

Jeffrey C Rastatter

✉ JRastatter@luriechildrens.org

MD, University of Illinois at Chicago,
Department of Otolaryngology-Head & Neck
Surgery, 1855 W Taylor St. Chicago, IL 60612,
USA

Tel: +312-996-1545; +765-532-156

Fax: 312-996-3260

Keywords: Mandibular distraction osteogenesis; Micrognathia; Pierre robin sequence; Synchronous airway lesions; Direct laryngoscopy; Bronchoscopy

Received: October 19, 2015, **Accepted:** December 03, 2015, **Published:** December 10, 2015

Introduction

Micrognathia is a congenital anomaly that can result in glossoptosis, cleft palate and upper airway obstruction. The resultant anatomical disruptions often lead to respiratory and feeding difficulties in the newborn and acute events in and out of the operating room that could be avoidable.

There are a variety of surgical and non-surgical options for airway management in a child with micrognathia. Conservative measures include prone positioning, placement of a nasal pharyngeal airway (nasal trumpet), and positive pressure mask ventilation. Surgical options include tongue-lip adhesion, glossopexy or hyomandibulopexy, and tracheotomy [1-3]. More recently, Mandibular Distraction Osteogenesis (MDO) has been introduced for relieving tongue based airway obstruction. Multiple studies have demonstrated the relief of upper airway obstruction using MDO [4-9].

MDO involves gradually lengthening the mandible after the initial osteotomy. Bony segments are separated by small increments during the distraction phase, and this process induces new bone formation in the resulting gap. Related muscles, nerves, blood vessels and mucosa are also elongated in the process. After lengthening, there is a consolidation period in which the bony segments are held in their advanced position [1,4,10]. Many studies have shown an improvement in upper airway obstruction after MDO [11-14]. However, it has not been investigated whether there are Synchronous Airway Lesions (SALs) coexistent to micrognathia which could be contributing to the patient's symptoms both acutely and over the lifetime of the patient. The purpose of this study primarily is to determine the prevalence of SALs in patients who have undergone MDO and to determine if these impact the surgical success rate for MDO.

Methods

A retrospective review of all pediatric patients who underwent MDO and bronchoscopy from January 1, 2001 to December 31, 2011 at Lurie Children's Hospital of Chicago was performed. Approval from the Institutional Review Board at Lurie Children's Hospital was obtained. We utilized a computer medical record search using current procedure terminology codes for distraction osteogenesis. Patients who underwent distraction for purposes other than mandibular lengthening were excluded. Fifty-four patients were identified who had undergone MDO. A total of 21 patients had both MDO and Direct Laryngoscopy with Bronchoscopy (DLB). The remaining 33 patients had MDO but no formal airway evaluation with DLB.

Patient information collected included sex, prematurity/gestational age, age at DLB, age at MDO, presence/type of craniofacial anomalies, presence/type of syndrome, and other respiratory diagnoses. DLB operative reports were used to determine the type and presence of SALs. In addition, tracheostomy status and success of MDO were also recorded. Success of MDO was specified by tracheostomy decannulation in patients who received a tracheostomy prior to MDO, or clinical improvement and tracheostomy avoidance in patients who received MDO as a first intervention.

Surgical Technique of Airway Evaluation

DLB was performed with an age-appropriate laryngoscope and rigid bronchoscope (Karl Storz, Tuttlingen, Germany) under general anesthesia on a spontaneously breathing child. The subglottis was sized with endotracheal tubes as described by Cotton and Myer [15,16]. A full description of airway findings was documented in the operative report. When DLB was not possible due to poor laryngeal exposure from micrognathia, airway evaluation was done with transnasal fiberoptic laryngoscopy and fiberoptic bronchoscopy introduced through a laryngeal mask airway. In the small airways typical of neonates and infants, subglottic stenosis, laryngomalacia, laryngeal edema, tracheomalacia, bronchomalacia, tracheobronchitis and/or pulsatile airway compression can cause clinically notable airway obstruction (**Figure 1**).

Tracheobronchitis and laryngeal edema are diagnosed by the findings of mucosal edema and cobblestoning on laryngoscopy and bronchoscopy. These seemingly simple ailments can be seen in the context of acute infection (bacterial, viral) in patients that exhibit other symptoms of acute infection (fevers, malaise, purulence, URI symptoms) or more rarely chronic infection. In the absence of infection, these SALs can be an effect of laryngopharyngeal reflux. These are well studied and treatable airway lesions [15,17-19].

Results

During the study period, 54 patients underwent MDO. Thirty-three patients (61.1%) did not have a DLB performed. Twenty-one patients (38.9%) had DLB preoperatively.

We were primarily interested in those 21 patients that underwent MDO with DLB performed at or before the time of surgery. Of these patients, there were 11 males (52.4%) and 10 females (47.6%). Prematurity was noted in 23.8% of the patients, with the average gestational age of 34 weeks. Age at MDO ranged from 1 month to 14.3 years with a mean of 34.9 months (median of 15

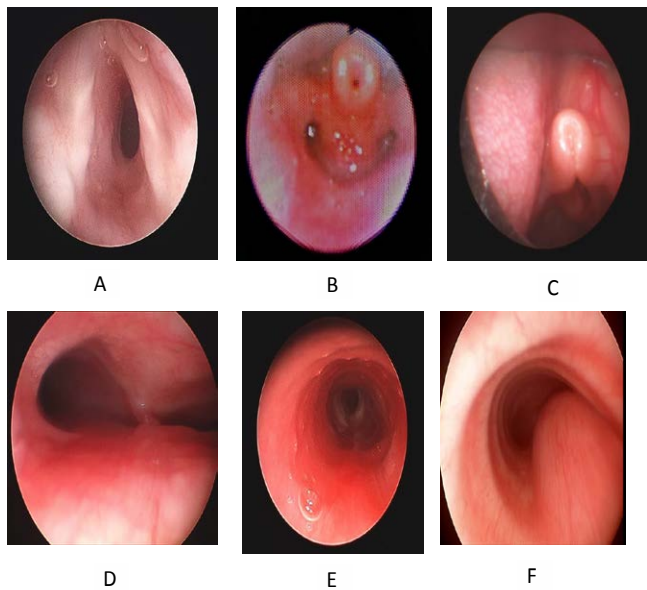


Figure 1 Examples of obstructive airway lesions. A: Subglottic stenosis, B and C: Laryngomalacia with edema, D: Bronchomalacia and tracheomalacia, E: Tracheobronchitis with reactive airway F: Pulsatile airway compression. These SALs are dynamic and can worsen at peak inspiration and/or expiration.

months). Age at DLB ranged from less than one month to 14.3 months, with a mean of 36.2 months (median of 11 months). Craniofacial anomalies of the patients are described in (Table 1). Micrognathia was noted in 100% (21/21) of our patients, cleft palate in 61.90% (13/21), midface hypoplasia in 28.57% (6/21), craniosynostosis in 4.76% (1/21), pyriform aperture stenosis in 4.76% (1/21), and choanal stenosis/atresia in 4.76% (1/21). Diagnosed syndromes in the patients are described in (Table 2). Pierre-Robin sequence was noted in 61.90% (13/21), Nager syndrome in 14.29% (3/21), Stickler syndrome in 14.29% (3/21), Goldenhar syndrome in 9.52% (2/21), Mobius syndrome in 4.76% (1/21), and Cornelia de Lange syndrome in 4.76% (1/21). Two (9.52%) of the patients had a diagnosis of asthma, but no other significant pulmonary pathology was identified.

Fifteen of the 21 children (71.4%) were found to have at least 1 SAL. Specific SALs include 12 (57.1%) children with laryngeal edema, 9 (42.9%) with tracheobronchitis, 7 (33.3%) with laryngomalacia, 3 (14.3%) with tracheomalacia, 3 (14.3%) with bronchomalacia, 2 (9.5%) with subglottic stenosis, and 2 (9.5%) with pulsatile airway compression (Table 3). Nine of the 21 patients (42.9%) demonstrated what we consider a more significant SAL of subglottic stenosis, laryngomalacia, tracheomalacia, bronchomalacia or pulsatile airway compression. These lesions were considered more significant because they often cause more clinically significant airway obstruction and feeding difficulty independent of micrognathia due to severity of airway obstruction often seen. Nineteen (90.5%) of this subgroup had a tracheostomy placed prior MDO due to airway obstruction. Eighteen out of those 19 patients with a preoperative tracheostomy were able to be decannulated (94.7%). The one patient that was not decannulated had two synchronous airway

Table 1 Number of patients with an associated craniofacial anomaly.

Number of patients with an associated craniofacial anomaly		
Type of finding	Number of Patients	Percentage
Micrognathia	21	100.00%
Cleft palate	13	61.90%
Midface hypoplasia	6	28.57%
Craniosynostosis	1	4.76%
Pyriform aperture stenosis	1	4.76%
Choanal stenosis/atresia	1	4.76%

Table 2 Distribution by specific syndrome associated with each patient that underwent both MDO and DLB.

Distribution by specific syndrome associated with each patient that underwent both MDO and DLB		
Type of finding	Number of Patients	Percentage
Pierre Robin	13	61.90%
Nager	3	14.29%
Stickler	3	14.29%
Goldenhar	2	9.52%
Mobius	1	4.76%
Cornelia de Lange	1	4.76%

Table 3 Distribution of synchronous airway lesions in patients that underwent both MDO and DLB.

DLB Findings		
Type of finding	Number of Patients	Percentage
Any SAL	15	71.40%
Laryngeal Edema	12	57.10%
Tracheobronchitis	9	42.90%
Laryngomalacia	7	33.30%
Tracheomalacia	3	14.30%
Bronchomalacia	3	14.30%
Subglottic Stenosis	2	9.50%
Pulsatile airway compression	2	9.50%

lesions noted on bronchoscopy which were tracheobronchitis and laryngeal edema. Two patients did not require tracheostomy and one of those patients failed because of lack of clinical improvement in nighttime obstructive episodes and required nighttime positioning and a nasal trumpet. The patient that was considered a failure due to lack of clinical improvement had a SAL of prominent laryngeal edema noted on direct laryngoscopy.

In addition, we further separated this subgroup into two separate age groups (age <or>24 months). Patients <24 months old (n=14) demonstrated a prevalence of SALs of 78.6% versus 57.1% for patients >24 months old. Patients <24 months old also showed a higher predilection for more significant synchronous airway lesions (subglottic stenosis, laryngomalacia, tracheomalacia, bronchomalacia, pulsatile airway compression) with a prevalence of 50% (7/14) versus 28.57% (2/7) for older children.

Results of the 33 patients who underwent MDO but did not have a bronchoscopy were also evaluated. Seventeen of the 33 patients were female (51.5%). Only 1 of the 33 children was born premature. The date of MDO was able to be confirmed on 27 of the 33 patients due to paucity of follow up data. The age of MDO in these 27 patients ranged from 3 weeks to 19 years

old with a mean of 98 months (median of 72 months). Thirty of the 33 patients (90.9%) were noted to have micrognathia, while the other 3 patients had MDO performed in conjunction with other orthognathic or midface procedures. Twelve of the 33 patients (36.4%) had cleft palate. Ten of the 33 patients (33.3%) had midface hypoplasia. Only one of these patients had craniosynostosis (3%). Seven (21.2%) of these patients had Pierre Robin sequence, four (12.1%) had Goldenhar Syndrome, one had Nagar (3.0%) syndrome, one (3.0%) had Crouzons and one (3.0%) had Aperts syndrome. Six of the 33 (18.2%) patients required tracheostomy. Of those six, 4 (66.7%) were decannulated after MDO.

Discussion

The use of MDO in alleviating upper airway obstruction in infants with micrognathia is well established. The literature supports that patients often have multiple airway abnormalities present [19-22]. The primary reason for endoscopic evaluation prior to MDO is to establish if there are SALs that if correctable can contribute to better outcomes of MDO.

DLB is among the most common procedures performed by pediatric otolaryngologists, and has a very low rate of adverse events when performed by appropriately trained surgeons. Potential adverse events from DLB are rare but include airway edema, coughing, respiratory difficulty, bronchospasm, hemorrhage, airway trauma and scarring, and pneumothorax.

We have examined the prevalence of SALs in micrognathic children undergoing MDO. SALs were identified in 71% of children. The age and demographics of our study population has evolved as it has in many other craniofacial centers. We included patients in the study shortly after the procedure became popularized. These patients tended to be older as MDO was not an available early in their lives. In more recent years the patients are typically neonates or infants with a trend to avoid tracheostomy when possible. We created a subgroup of patients to demonstrate this progression. This subgroup demonstrated that younger patients (age < 24 months) showed an even higher prevalence of all SALs (78.6%). The high rate of SALs in this group suggests that the airway compromise is often multifocal in these children and is an important factor that should be considered in both acute anesthetic care and anesthetic care over the lifetime of the patient. If severe, SALs can lead to consideration for surgical intervention independent of micrognathia and thus the combined effect is appreciated. Interventions may include supraglottoplasty for laryngomalacia, laryngotracheal reconstruction for subglottic stenosis, and cardiothoracic surgery for pulsatile airway compression. Tracheostomy may be indicated with severe tracheobronchomalacia or with the other significant SALs if they are severe and other interventions are unsuccessful or unavailable.

Of the two failures after MDO, one patient was tracheostomy dependent and could not be decannulated. The other patient required further treatment with nighttime positioning and oronasal appliances due to lack of clinical improvement. Although this study includes a small number of patients a key point to the paper is that the patients that were considered failures from

an MDO perspective both had synchronous airway lesions. The patient that was not decannulated had two synchronous airway lesions noted on bronchoscopy; tracheobronchitis and laryngeal edema. The patient that had no clinical improvement of nighttime obstructions had significant laryngeal edema. It is possible that if these treatable lesions had been diagnosed preoperatively they could have been maximally treated and possibly contributed to better outcomes. It is also possible that if the SALs noted in the patients requiring tracheostomy were treated it may have contributed to earlier decannulation and possibly not requiring a tracheostomy at all. The failures noted cannot be fully attributed to the SALs alone. There is abundant literature and experience to conclude the airway lesions defined in this manuscript as SALs are important, demand evaluation, and should be considered in the overall management plan to relieve the airway and feeding symptoms in these patients. Due to the rarity of micrognathia and the low failure rate after MDO, many more patients will need to be evaluated to better establish the impact of SALs on the success rate for MDO in this population. The high rate of SALs identified in this study along with our knowledge of the potential airway and feeding consequences of these types of lesions, is sufficient to recommend full airway evaluation including DLB in all patients with micrognathia and airway obstruction. With full airway evaluation the rare patient with micrognathia and a severe SAL will have appropriate consideration and management of the SAL, and more appropriate decisions from a surgical and anesthetic perspective can therefore be made regarding the potential indication and timing of MDO.

A limitation of this study is the retrospective nature and relatively large number of the patients undergoing MDO without DLB. The patients who did not receive DLB were on average older. That fact that 6/33 (18.2%) of this subgroup required tracheostomy may offer some explanation as to why these patients did not undergo DLB. It is possible that this subgroup of patients without DLB was clinically less severe from an obstructive airway perspective. Without this information, our calculated rates of SALs in this study may over or under-estimate the SAL rates in all patients that received MDO during the study period.

Another limitation of the study is the lack of a control group. This study did not include a control group because the purpose was to identify the prevalence of SALs in patients undergoing MDO. We are focusing future research on determining the impact of SALs on the success of MDO which requires a larger patient population with a longer time period of coverage. This is possibly most attainable by a multi-institutional study due to the low incidence of MDO. We are hopeful this current study will give justification and interest for other to join a larger multi-institutional study.

All patients that had an otolaryngologist as part of the treatment team received a full airway evaluation, including laryngoscopy and bronchoscopy, before or at the time of the MDO procedure. The patients that did not have full airway evaluation were managed by a treatment team that did not involve an otolaryngologist. This was more often the case earlier in the study period as over time there was increased recognition of the benefit of utilizing a full airway evaluation as part of the overall planning of the most appropriate treatment strategy in these patients. For the purpose

describing the type and frequency of SALs that can only be reliably diagnosed on laryngoscopy and bronchoscopy, patients who did not have DLB were necessarily excluded from this portion of the analysis. This exclusion amounted to 33 patients and raises 2 important questions.

The first being why didn't these patients receive full airway evaluation? The second being did these patients have SALs at a similar incidence to the patients that were included in the study. Question 1 is difficult to answer with certainty in a retrospective study. One possibility is these patients were not recommended to have a full airway evaluation as their airway obstructive symptoms may have been milder. However, while other symptoms of micrognathia are important (dysphagia, cosmetic appearance), airway obstruction is often a primary driver of the decision to intervene whether by MDO or another treatment. It is likely, therefore, these 33 patients had some degree of airway obstruction. Another contributing factor related to a plausible answer to question 1 is early in the study period the benefit of full airway evaluation was not as well recognized, and the decision to treat with MDO was made without otolaryngology airway assessment. Lending support to this idea is the more recent patients in the study period did have full airway evaluation, and full airway evaluation is currently part of our team's standard protocol for evaluation and management of new micrognathic

patients. Question 2 is also difficult to answer as these patients did not have full airway evaluation. While the lack of laryngoscopy and bronchoscopy information on these 33 patients necessitates their exclusion from analysis to identify synchronous airway lesions, the information obtained from the patients who did have full airway evaluation and underwent MDO is still important, useful, and brings us closer to an understanding of the range of airway anomalies that can impact such patients and influence treatment decisions. Our treatment team now incorporates full airway evaluation, including laryngoscopy and bronchoscopy, in the workup of all patients undergoing MDO for airway obstruction. We feel the incidence of synchronous airway lesions in this study is sufficient to justify a recommendation for other treatment teams to consider incorporating this airway evaluation to all patients with such anomalies. Moving forward we will then be able to fully establish the true incidence and significance of synchronous airway lesions in these patients.

Conclusion

There is a high rate of SALs in patients undergoing mandibular distraction surgery, with most common being laryngeal edema, tracheobronchitis, and laryngomalacia. DLB should be considered preoperatively for patients undergoing MDO as it has the potential to diagnose other treatable causes of airway obstruction that may affect surgical and anesthetic outcomes.

References

- 1 Meyer AC, Lidsky ME, Sampson DE, Lander TA, Liu M, et al. (2008) Airway interventions in children with Pierre Robin Sequence. *Otolaryngol Head Neck Surg.* 138: 782-787.
- 2 Mackay DR (2011) Controversies in the diagnosis and management of the Robin sequence. *J Craniofac Surg.* 22: 415-420.
- 3 Glynn F, Fitzgerald D, Earley MJ, Rowley H (2011) Pierre Robin sequence: an institutional experience in the multidisciplinary management of airway, feeding and serous otitis media challenges. *Int J Pediatr Otorhinolaryngol.* 75: 1152-1155.
- 4 Judge B, Hamlar D, Rimell FL (1999) Mandibular distraction osteogenesis in a neonate. *Arch Otolaryngol Head Neck Surg.* 125: 1029-1032.
- 5 Sidman JD, Sampson D, Templeton B (2001) Distraction osteogenesis of the mandible for airway obstruction in children. *Laryngoscope.* 111: 1137-1146.
- 6 Izadi K, Yellon R, Mandell DL (2003) Correction of upper airway obstruction in the newborn with internal mandibular distraction osteogenesis. *J Craniofac Surg.* 14: 493-499.
- 7 Hong P (2011) A clinical narrative review of mandibular distraction osteogenesis in neonates with Pierre Robin sequence. *Int J Pediatr Otorhinolaryngol.* 75: 985-991.
- 8 Cheng AT, Corke M, Loughran-Fowlds A, Birman C, Hayward P, et al. (2011) Distraction osteogenesis and glossopepy for Robin sequence with airway obstruction. *ANZ J Surg.* 81: 320-325.
- 9 Denny AD (2001) Mandibular distraction osteogenesis in very young patients to correct airway obstruction. *Plast Reconstr Surg.* 108: 302-211.
- 10 Bookman LB, Melton KR, Pan BS, Bender PL, Chini BA, et al. (2012) Neonates with tongue-based airway obstruction: a systematic review. *Otolaryngol Head Neck Surg.* 146: 8-18.
- 11 Denny AD (2004) Distraction osteogenesis in Pierre Robin neonates with airway obstruction. *Clin Plastic Surg.* 31: 221-229.
- 12 Mandell DL, Yellon RF, Bradley JP, Izadi K, Gordon CB (2004) Mandibular distraction for micrognathia and severe upper airway obstruction. *Arch Otolaryngol Head Neck Surg.* 130: 344-348.
- 13 Tibesar RJ, Price DL, Moore EJ (2006) Mandibular distraction osteogenesis to relieve Pierre Robin airway obstruction. *Am. J. Otolaryngol.* 27: 436-439.
- 14 Tibesar RJ, Scott AR, McNamara C, Sampson D, Lander TA, et al. (2010) Distraction osteogenesis of the mandible for airway obstruction in children: long-term results. *Otolaryngol Head Neck Surg.* 143: 90-96.
- 15 Myer CM, O Connor DM, Cotton RT (1994) Proposed grading system for subglottic stenosis based on endotracheal tube sizes. *Ann Otol Rhinol Laryngol.* 103: 319-323.
- 16 Mahrous MA, Al Bishri A, Haroun MA (2011) Distraction osteogenesis as followed by CT scan in Pierre Robin sequence. *J. Craniomaxillofac Surg.* 39: 412-419.
- 17 Olson TP, McMurray JS, Mount DL (2011) Endoscopic changes in the upper airway after mandibular distraction osteogenesis. *J Craniofac Surg.* 22: 105-109.
- 18 Knapp K, Powitzky R, Digoy P (2011) Subglottic stenosis: another challenge for intubation and potential mechanism of airway obstruction in Pierre Robin Sequence. *Int J Pediatr Otorhinolaryngol.* 75: 1075-1077.
- 19 Mandell DL, Yellon RF (2007) Synchronous airway lesions and esophagitis in young patients undergoing adenoidectomy. *Arch Otolaryngol Head Neck Surg.* 133: 375-378.
- 20 Rastatter JC, Schroeder JW Jr, French A, Holinger L (2011) Synchronous airway lesions in children younger than age 3 years undergoing adenotonsillectomy. *Otolaryngol Head Neck Surg.* 145: 309-313.
- 21 Krashin E, Ben-Ari J, Springer C, Derowe A, Avital A, et al. (2008) Synchronous airway lesions in laryngomalacia. *Int J Pediatr Otorhinolaryngol.* 72: 501-507.
- 22 Schroeder JW Jr, Bhandarkar ND, Holinger LD (2009) Synchronous airway lesions and outcomes in infants with severe laryngomalacia requiring supraglottoplasty. *Arch Otolaryngol Head Neck Surg.* 135: 647-651.